



Comprehensive Medical and Dental Program Authorization Guideline

TITLE

Cranial Banding Prior Authorization Guideline

RESPONSIBLE AREA

Health Services

History of Review: 1/12, 3/13, 8/15/13, 3/20/14, 3/5/15, 7/1/16, 9/1/17, 12/9/18; 06/03/19

Approval Date: 06/03/19

DESCRIPTION

This guideline is used in the prior authorization and decision-making process regarding requests for cranial banding.

DEFINITIONS

Plagiocephaly is a type of cephalic disorder characterized by an asymmetrical distortion (flattening) of one side of the skull. It is a common finding at birth and may be the result of a restrictive intrauterine environment. If there is premature union of skull bones, craniosynostosis can be a cause of plagiocephaly.

Positional Plagiocephaly, also known as deformational plagiocephaly, is a condition most commonly found in infants and is characterized by a flat spot on the back or one side of the head caused by remaining in one position for too long. It can be caused by a condition called torticollis in which neck muscles on one side of the head develop differently, causing the head to tilt to one side, but more commonly it happens in infants of ordinary development who sleep in one position for long periods of time. Prognosis for this condition is excellent and can be reversed in most cases before one year of age. Treatment can be as simple as repositioning the child's head while sleeping and increasing the time spent on the belly. In some cases, special fitted helmets can be used. Once a child starts moving on his/her own, the condition may improve by itself. The flattening of the head, while alarming, does not typically harm the brain or hinder its development.

Brachycephaly refers to shortened antero-posterior diameter of the skull.

Dolichocephaly is a condition where the head is longer than expected relative to the width.

Cranial Bands are usually made of an outer hard shell with a foam lining. Gentle, persistent pressures are applied to capture the natural growth of an infant's head, while inhibiting growth in the prominent areas and allowing for growth in the flat regions. As the head grows, adjustments are made frequently. The helmet essentially provides a tight, round space for the head to grow into. Cranial band use is ideally done between 4 months and 12 months of age and is designed to be used for approximately 2 – 4 months.

CLINICAL GUIDELINE**Appropriate Patient Selection**

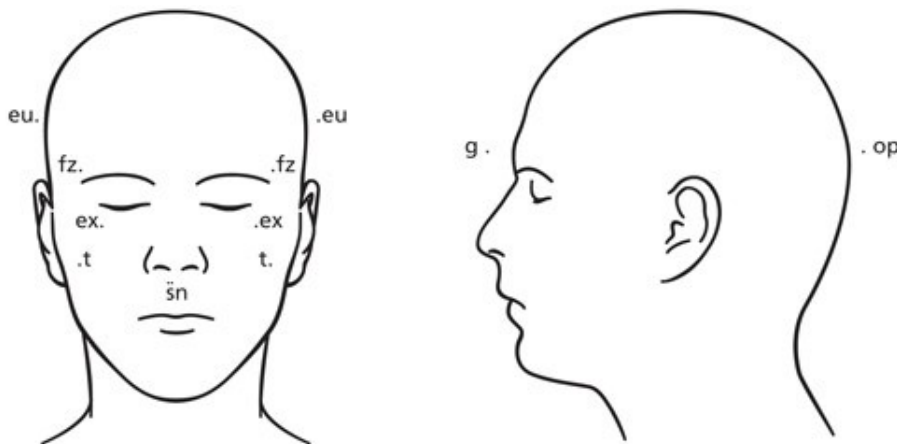


Cranial bands are considered medically necessary for moderate to severe positional head deformities associated with prematurity, restrictive intra-uterine positioning, cervical abnormalities, torticollis and sleep positioning in children under certain circumstances:

A two-month trial of conservative therapy has failed

- Repositioning of child's head away from the preferred side
- Treatment of torticollis with physical therapy
- Documentation of pediatric visits and assessment by an experienced clinician

If a two-month trial has failed, cranial orthotics may be instituted if one of the following criteria is met:



For Plagiocephaly:

Anthropometric data verifies that a moderate to severe plagiocephaly exists. (Data may be obtained by orthotist).

Asymmetry of greater than 6mm between anthropometric measurements of cranial base (sn – t), cranial vault (fz – eu), or orbitotragal (ex – t) depth warrant a trial of cranial banding.

For Brachycephaly:

A brachycephalic skull is relatively broad and short (typically with the breadth at least 80% of the length). The evaluation for this consists of obtaining a cephalic index.

Cephalic Index = $\frac{\text{Head width (eu – eu)}}{\text{Length}} \times 100$

A cephalic index greater than 2 standard deviations above or below the mean warrants a trial of cranial banding.



	Age	-2SD	-1SD	Mean	+1SD	+2SD
Male	16 days to 6 months	63.7	68.7	73.7	78.7	83.7
	6 - 12 months	64.8	71.4	78.0	84.6	91.2
Female	16 days to 6 months	63.9	68.6	73.3	78.0	82.7
	6-12 months	69.5	74.0	78.5	83.0	87.5

Other factors which may warrant cranial orthotic include:

Premature infants with dolichocephalic head shape (a dolichocephalic skull is a relatively long skull, specifically having a cephalic index of < 75% for females and < 65% for males) secondary to sustained position

- Infants with misshapen head secondary to constant head position required for hyperalimentation
- Infants with residual plagiocephaly after surgical correction
- Infants with massive hydrocephalus who continue to have increasing head size despite neurosurgical management with one or more Ventriculo-Peritoneal (VP) shunt.

REFERENCES

www.aetna.com/cpb/medical/data/300_399/0379.html

Diagnosis and Management of Posterior Plagiocephaly. Ian F. Pollack, H. Wolfgang Losken and Patricia Fasick. Pediatrics 1997;99;180-185.

Prevention and Management of Positional Skull Deformities in Infants. John Persing, Hector James, Jack Swanson, John Kattwinkel, Committee on Practice and Ambulatory Medicine, Section on Plastic Surgery and Section on Neurological Surgery. Pediatrics 2003;112;199-202

PLEASE NOTE: State and Federal law take precedence over prior authorization guidelines. CMDP reserves the right to review and update guidelines periodically.